

A case of bilateral chylothorax owing to bilateral subclavian vein thrombosis

Babaji Ghewade, Smaran Cladius, Ulhas Jadhav, Swapnil Chaudhari

Department of Respiratory Medicine, JN Medical College, Sawangi Meghe, Wardha, Maharashtra, India.
Correspondence to: Babaji Ghewade, E-mail: bghewade@rediffmail.com

Received November 15, 2015. Accepted November 29, 2015

Abstract

Chylothorax is defined by the presence of chyle in the pleural space, which denotes a leakage of lymphatic fluid from the thoracic duct or its tributaries. The various causes of chylothorax include trauma, malignancies such as lymphomas, miscellaneous causes including tuberculosis and idiopathy. Here, we report a case of bilateral chylothorax in a female patient, which resulted owing to bilateral subclavian vein thrombosis that subsided completely after treatment with anti-coagulants.

KEY WORDS: Chylothorax, subclavian vein obstruction, triglycerides

Introduction

Chylothorax is a condition characterized by the presence of chyle in the pleural cavity.^[1] A leakage of lymphatic fluid from the thoracic duct or its tributaries is responsible for the presence of chyle in the pleural cavity.^[2] Thoracic duct carries 60%–70% of ingested fat from the intestine to the circulatory system via the cisterna chyli near the junction of the left jugular and subclavian veins. As a result, chyle contains great amounts of cholesterol, triglycerides, chylomicrons, and fat soluble vitamins.^[3] Interference of these lymphatic channels at any place along their path can lead to a pleural effusion. Lymphatic fluid also contains a high content of lymphocytes and immunoglobulins.^[2] Chylothorax can be classified as traumatic or nontraumatic.^[4] Among them, bilateral subclavian vein thrombosis and obstruction of the veins are uncommon causes for chylothorax.^[1]

Majority of the patients may present with unilateral effusions, either right (50%) or left sided (33.3%), but bilateral

effusions may be there in other patients (16.66%). It also depends on the location of the leak. Injury to the duct above the fifth thoracic vertebra leads to a left-sided effusion, whereas damage to the duct below this level results in a right-sided effusion.^[5] Clinically, patients may have dyspnea, chest pain, and cough as in any other pleural effusion cases.

Here, we report a case of a middle-aged female subject with bilateral chylothorax (L>R) owing to bilateral subclavian vein thrombosis.

Case Report

A 32-year-old lady was admitted with chief complaints of breathlessness grade II MMRC since 2 months, abdominal pain since 1 month, and loss of appetite since 1 month. Patient gave history of laparoscopic hysterectomy 4 months back.

On examination, patient was overweight with BMI of 25.1 kg/m². There was no pallor, icterus, clubbing, cyanosis, lymphadenopathy, and pedal edema. Her pulse was 94/min, regular, and normovolemic, and peripheral pulses were felt bilaterally. Respiratory rate was 26/min, thoracoabdominal, blood pressure was 110/74 mm Hg in right arm in supine position, and oxygen saturation was 98% on room air.

Upper respiratory tract examination was normal. Upper anterior chest wall showed dilated veins. In lower respiratory tract, trachea was slightly shifted to right side, breath sounds were absent on left infra-axillary, infrascapular, interscapular, and right infrascapular areas. There was stony dull note on left side over abovementioned areas. On the right side, there

Access this article online

Website: <http://www.ijmsph.com>

DOI: 10.5455/ijmsph.2016.15112015276

Quick Response Code:



were absence of breath sounds over infrascapular area, and stony dull note was present over the same area. Clinical diagnosis of bilateral pleural effusion of moderate size was made.

Chest X-Ray (PA view) [Figure 1] confirmed bilateral pleural effusion (L>R). Her laboratory investigations showed hemoglobin 11.6 gm%, WBC 7400/cm with 78% neutrophils, normal platelet counts, and ESR 67 mm at the end of 1 h. Liver and kidney function tests were normal along with normal blood sugar, and ELISA test for HIV was nonreactive.

The pleural fluid was aspirated. Appearance was milky white [Figure 2]. It showed pH 7.4, proteins 5.6 gm%, lactate dehydrogenase (LDH) 272 IU, sugar 144 mg%, TLC 1980, DLC N-10% L-90%, ADA 26 IU, triglycerides 444 mg/dL, and there was no growth on culture. Cytology showed sparse number of cells (lymphocytes) and few leukocyte colonies in lipid vacuolated background. Cytomorphology was consistent with chylous fluid.

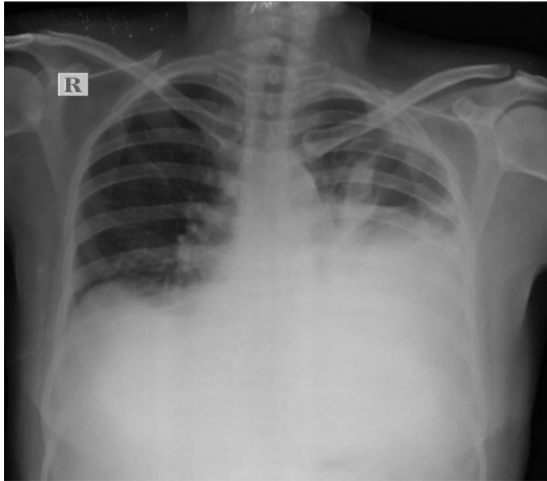


Figure 1: Chest X-ray showing B/L pleural effusion (L>R).

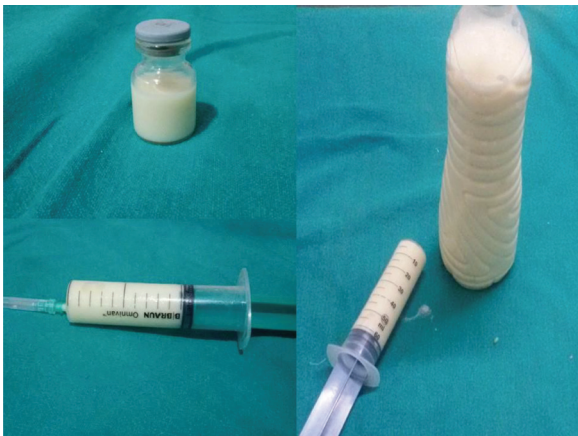

Figure 2: Chylous pleural fluid.

Diagnosis of bilateral chylothorax was made, and further investigations were undertaken to determine the causative factor. Serum ANA was negative, Mantoux test was nonreactive, TSH 1.20 mIU/L, C-reactive protein 59.1 mg/dL, and cancer antigen 125 of ascitic fluid was negative. Ultrasonography of abdomen and pelvis showed presence of minimal ascites with bilateral pleural effusion and edematous gall bladder. Contrast-enhanced computed tomography of abdomen and pelvis showed loculated, nonenhancing collection measuring 8.0 × 6.4 cm noted in the pelvis site of postoperative collection. High resolution computed tomography of thorax [Figure 3] showed B/L pleural effusion with basal atelectasis with ascites. Bone marrow showed normal study.

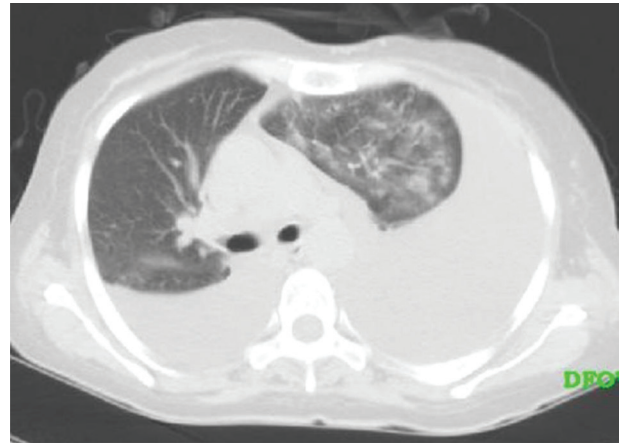


Figure 3: HRCT thorax showing B/L pleural effusion.

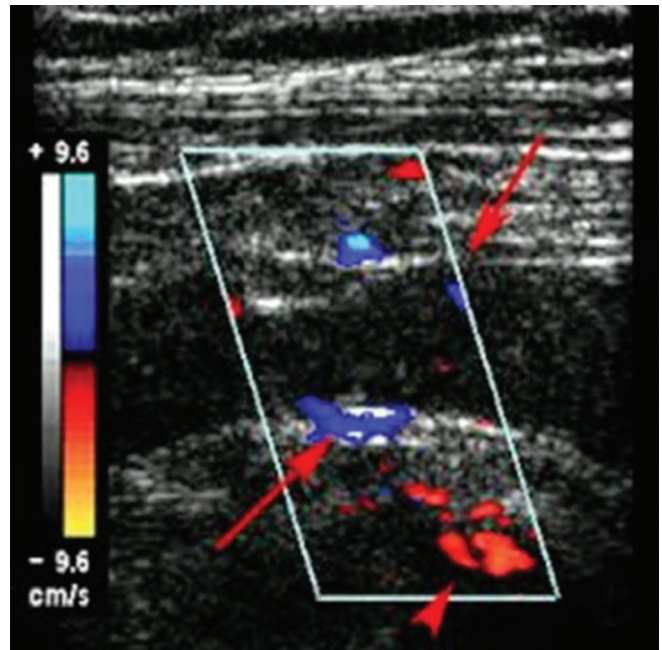


Figure 4: Doppler study.

Lymphangiography was performed, which showed normal lymphatic vessels in lower limbs, new enlarged lymph nodes in inguinal and retroperitoneal regions. Visualized thoracic duct was normal. No evidence of leakage or rupture of thoracic duct at any site was found.

USG neck showed thrombosis of right common jugular vein extending into the external jugular vein.

Triplex color doppler study revealed complete thrombosis of right internal jugular vein, right proximal brachiocephalic vein with partial thrombosis in right subclavian vein. Partial thrombosis of left brachiocephalic vein, proximal left subclavian vein, and proximal left internal jugular vein with plaque in left internal jugular vein causing 30%–40% luminal narrowing was also observed [Figure 4].

Final diagnosis of bilateral chylothorax (L>R) owing to bilateral subclavian vein thrombosis was made.

During 2 months of hospital stay, 30 L of chylous pleural fluid and 3 L chylous ascitic fluid were aspirated. Patient was put on restricted fatty food diet. Low-molecular-weight heparin was given in view of thrombosis. Somatostatin was given in view to decrease lymphatic flow and triglyceride absorption. Patient improved with treatment and follow-up. Chest X-Ray (PA view) showed mild bilateral pleural effusion (L>R). After 4 months of follow-up, patient is now completely alright, and there is no recurrence of pleural effusion.

Discussion

Chylothoraces usually present as unilateral effusions, but 20% may be bilateral.^[1] Because of the noninflammatory nature of chyle, patients do not experience pleuritic chest pain but present with dyspnea. The pleural fluid appears free-flowing and nonoculated without pleural thickening on imaging studies. Pleural fluid is grossly white, milky, and opalescent but may be serous or serosanguineous when patients are fasting. Pleural fluid analysis demonstrates a lymphocyte predominant exudate with an elevated protein but not LDH. Pleural fluid triglyceride concentration is usually above 110 mg/dL.

Chyle in the pleural space was first described by Bartolet in 1633, and, since its initial description, numerous causes have been well-described, among which trauma and malignancies are the leading causes. Subclavian vein thrombosis is nowadays becoming one of the common causes, and such cases have been reported.^[6] Isik *et al.*^[7] found chylothorax as a complication of central venous catheterization. Warren *et al.*^[8] reported chylothorax secondary to obstruction of the superior vena cava: a complication of the LeVein shunt.

Chylothorax has been identified as a complication of thrombosis of the superior vena cava in experimental studies and by clinical observation.^[9–12] Blalock *et al.*^[13] in 1943 showed that acute interruption of the superior vena cava led to the development of a chylothorax in 60% of cats and dogs. Chylothorax has been reported in man as a complication of spontaneous thrombosis or obstruction of the superior vena cava, innominate vein, or subclavian vein.^[1]

There are other lymphatic abnormalities such as lymphangioleiomyomatosis in which 10%–40% of patients develop pleural effusions that are almost always chylous.^[1] Effusions may be unilateral or bilateral, and chyloptysis may also occur.^[14,15]

In this case, most of the other causes such as trauma, malignancy, tuberculosis, and sarcoidosis were ruled out, and bilateral subclavian vein thrombosis was established as a cause of chylothorax. Furthermore, after starting anticoagulants, the rate of formation of pleural fluid was found to be diminished. Patient was discharged and followed up monthly. Today, patient is doing well and does not complain of any breathlessness and does not have any refilling of chylous fluid.

Conclusion

It is important to find out the cause of chylothorax. The causative factor should be ascertained, because treatment will be according to the underlying pathogenesis. When trauma, malignancy, and tuberculosis are ruled out, thrombosis of subclavian veins or superior vena cava should be considered as a cause of chylothorax.

References

1. Mayse ML. Non-malignant pleural effusions. In: *Fishman's Pulmonary Diseases and Disorders*, Fishman AP (Ed.). New York: McGraw-Hill, 2008. pp. 1487–504.
2. Ryu JH, Tomassetti S, Maldonado F. Update on uncommon pleural effusions. *Respirology* 2011;16(2):238.
3. Zilvermit DB. The composition and structure of lymph chylomicrons in dog, rat, and man. *J Clin Invest* 1965;44:1610–22.
4. Nair SK, Petko M, Hayward MP. Aetiology and management of chylothorax in adults. *Eur J Cardiothorac Surg* 2007;32:362–9.
5. Bessone LN, Ferguson TB, Burford TH. Chylothorax. *Ann Thorac Surg* 1971;12:527–50.
6. Light RW. Chylothorax and pseudochylothorax. In: *Pleural Diseases*, Light RW (Ed.). Baltimore: Williams and Wilkins, 1995. pp. 284–98.
7. Isik Y, Goktas U, Binici O, Kati I. Chylothorax developing due to thrombosis in the subclavian vein. *Eur J Gen Med* 2013;10(4):243–5.
8. Warren WH, Altman JS, Gregory SA. Chylothorax secondary to obstruction of the superior vena cava: a complication of the LeVein shunt. *Thorax* 1990;45:978–9.
9. Thurer RJ. Chylothorax: a complication of subclavian vein catheterization and parenteral hyperalimentation. *J Thorac Cardiovasc Surg* 1976;71(3):465–8.
10. Kramer SS, Taylor GA, Garfinkel DJ, Simmons MA. Lethal chylothoraces due to superior vena caval thrombosis in infants. *AJR Am J Roentgenol* 1981;137(3):559–63.
11. Seibert JJ, Golladay ES, Keller C. Chylothorax secondary to superior vena cava obstruction. *Pediatr Radiol* 1982;12(5):252–4.
12. Vain NE, Swarner OW, Cha CC. Neonatal chylothorax: a report and discussion of nine consecutive cases. *J Pediatr Surg* 1980; 15(3):261–4.
13. Blalock A, Cunningham RS, Robinson CS. Experimental production of chylothorax by occlusion of the superior vena cava. *Ann Surg* 1936;104(3):359–64.

14. Foley WJ, Elliott JP Jr, Smith RF, Reddy DJ, Lewis JW, Hageman JH. Central venous thrombosis and embolism associated with peritoneovenous shunts. *Arch Surg* 1984;119(6): 713–20.
15. Ryu JH, Doerr CH, Fisher SD, Olson EJ, Sahn SA. Chylothorax in lymphangioliomyomatosis. *Chest* 2003;123(2):623.

How to cite this article: Ghewade B, Cladius S, Jadhav U, Chaudhari S. A case of bilateral chylothorax owing to bilateral subclavian vein thrombosis. *Int J Med Sci Public Health* 2016;5: 1734-1737

Source of Support: Nil, **Conflict of Interest:** None declared.